https://doi.org/10.70882/274py740

SCIENCE FORUM (JOURNAL OF PURE AND APPLIED SCIENCES) 26, (5 Special) (2026), 849 - 859

Science Forum (Journal of Pure and Applied Sciences)

Journal Homepage: https://atbuscienceforum.com.ng/index.php/jpas

Gastroprotective, Antioxidant and Anti-Inflammatory Effects of Aloe Vera (Aloe Barbadensis Miller) Extract in Experimental Gastric Mucosal Injury in Mice

Ahmad S. M., Murtala Muhammad, Aminu Sulaiman Isah and Zainab Nana Mustapha.

Department of Biochemistry, Faculty of Science, Aliko Dangote University of Science and Technology, Wudil, Kano. State, Nigeria.

Abstract

Gastric mucosal injury is associated with disruption of epithelial defenses, oxidative stress and inflammatory signalling. Aloe vera (Aloe barbadensis Miller) has been investigated for antioxidant and anti-inflammatory properties. This report harmonizes two project datasets without pooling them: a primary dataset comprising gross gastric lesions, gastric-tissue superoxide dismutase (SOD), catalase (CAT), reduced glutathione (GSH), malondialdehyde (MDA) and histology, and a complementary dataset comprising serum tumour necrosis factor-alpha (TNF-a) and interleukin-6 (IL-6). Five groups were reported, including normal control, omeprazole, untreated ulcer control and Aloe vera extract at 150 or 300 mg/kg; three animals per group were represented in the available results. Gross lesions were recorded in 3/3 untreated ulcer-control animals, 2/3 at 300 mg/kg and 3/3 at 150 mg/kg, compared with 0/3 in the omeprazole group. SOD and CAT means were higher in extract-treated groups than in the untreated ulcer control, but group differences were not significant ($p = 0.425$ and $p = 0.593$, respectively). GSH and MDA results were inconsistent. MDA showed an omnibus ANOVA p-value of 0.048, but no significant Tukey pairwise differences and a non-significant Kruskal–Wallis's test ($p = 0.106$). In the complementary dataset, TNF-a and IL-6 means were lower in Aloe-treated groups than in the untreated ulcer control, but pairwise significance was not established. Histology showed mild-to-moderate changes, with normal architecture in 2/3 sections at 300 mg/kg. The datasets are not confirmed to share animals or identical protocols and were therefore not pooled. These small, exploratory datasets do not establish efficacy; animal-number discrepancies, incomplete ulcer-index data and protocol inconsistencies require resolution before definitive interpretation.

Keywords

Aloe Vera;
Gastric Mucosal Injury;
Gastric Ulcer;
Oxidative Stress;
Antioxidant Enzymes;
TNF-a;
IL-6;
Histopathology;
Mice

EISSN: 3156-5190 (Online)
ISSN: 1119-4618 (Print)
JPAS
Faculty of Science, ATBU Bauchi

Corresponding Author: Ahmad Shehu Muazu, Department of Biochemistry, Faculty of Science, Aliko Dangote University of Science and Technology, Wudil, Kano. State, Nigeria. Email: ahmadshehu@kust.edu.ng © 2026 Faculty of Science, ATBU Bauchi. All rights reserved

1. Introduction

Gastric ulceration is a disruption of the gastric mucosal lining that occurs when aggressive factors—including gastric acid, pepsin, ethanol and certain drugs—overwhelm mucosal defense mechanisms such as mucus and bicarbonate secretion, epithelial integrity, prostaglandin activity and adequate mucosal blood flow (Wallace, 2008; Lanas & Chan, 2017). Peptic ulcer disease remains clinically important because it can cause persistent symptoms and, in severe cases, bleeding or perforation (Sung et al., 2009).

Alcohol/ethanol-based experimental models produce acute mucosal injury associated with reactive oxygen species, lipid peroxidation, mitochondrial dysfunction, epithelial damage and inflammatory signalling. Oxygen-derived radicals have been implicated in ethanol-induced gastric-cell injury, and oxidative stress and mitochondrial damage may precede cell death (Mutoh et al., 1990; Hirokawa et al., 1998; Pan et al., 2008; Raish et al., 2021). Gastric oxidative status is commonly evaluated through MDA, a lipid-peroxidation marker, and endogenous antioxidant defenses such as SOD, CAT and GSH. These pathways can interact with repair and autophagic responses (Hernández-Muñoz et al., 2000; Chang et al., 2017).

Inflammation contributes to mucosal injury and repair. Cytokines such as TNF-α and IL-6 can amplify inflammatory responses and affect tissue damage and healing (Medzhitov, 2008; Tanaka et al., 2014). Cytokine measurement alongside biochemical antioxidant endpoints and histology can therefore provide complementary—though not interchangeable—information about an ulcerogenic challenge.

Aloe vera (Aloe barbadensis Miller) is a succulent plant whose leaf contains polysaccharides, including acemannan and glucomannan, along with phenolic compounds, flavonoids, chromones and anthraquinone-related constituents. These have been investigated for antioxidant, anti-inflammatory, immunomodulatory and tissue-protective activities; however, bioactivity varies with plant source, processing and preparation (Hamman, 2008; Cock, 2015; Liu et al., 2019; Sánchez et al., 2020; Sadgrove & Simmonds, 2021). Experimental studies have reported gastroprotective effects of Aloe preparations in ethanol- or alcohol-related gastric injury models, including changes in lesions, oxidative stress, inflammatory mediators, mucosal integrity and histology (Eamlamnam et al., 2006; Park et al., 2011, 2017; Werawatganon et al., 2014; Hussein et al., 2021; Mohamed et al., 2024).

Because preparations, doses, induction procedures and outcome measures vary between studies, results cannot be assumed to be directly comparable. The present report integrates two project datasets without statistical pooling: the primary dataset evaluates gross gastric lesions, gastric-tissue SOD, CAT, GSH and MDA, together with histology, after reported 14-day Aloe vera extract pretreatment; the complementary dataset reports serum TNF-α and IL-6 from a related project with a comparable group structure. The combined aim is to describe the findings comprehensively while transparently retaining the uncertainty regarding animal-cohort and protocol equivalence.

2. Materials and Methods

2.1 Study design, animals and reported sample size

The source reports a randomized laboratory experiment involving 25 adult male albino mice weighing approximately 20–30 g. Animals were obtained from the Department of Clinical Pharmacology and Therapeutics, Bayero University Kano, and maintained under standard housing conditions with a 12-hour light/dark cycle, standard feed and drinking water. A seven-day acclimatization period was reported. Five groups of five animals were reportedly allocated; however, biochemical and histological results available for harmonization represent three animals per group (n = 3; 15 animals

total). The disposition of the remaining ten animals must be clarified from study records.

2.2 Ethics

Ethical approval was reported from the Animal Care and Use Research Ethics Committee (ACUREC), Bayero University Kano. The two source documents contain different approval identifiers—BUK/ACUREC/CAP/UG231 and BUK/ACUREC/CAP/UG232—which must be reconciled with the original approval letter. The exact protocol and procedures authorised should be verified before submission. Animal research reporting should follow the ARRIVE 2.0 guidance (Percie du Sert et al., 2020).

2.3 Plant material and extract preparation

Fresh mature Aloe vera leaves were reportedly collected from the Department of Plant Science and Biotechnology, Bayero University Kano, in September 2026 and authenticated; voucher number BUKHAN0411 was reported. Leaves were washed, spiny margins and bases removed, and yellow latex drained for approximately 30 minutes. The leaf material was homogenized and extracted with 70% ethanol at a reported 1:5 (w/v) ratio, filtered through muslin and Whatman No. 1 filter paper, concentrated under reduced pressure/dried, and stored in an airtight amber container at 4 °C. The source does not report starting plant mass, dried extract mass or percentage yield; these should be added if available.

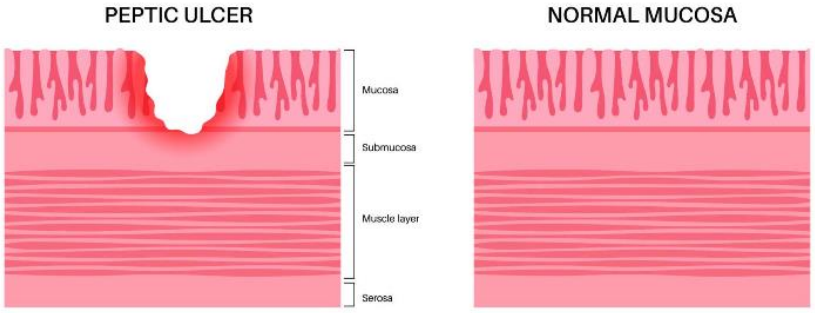

Figure 1. Schematic comparison of normal gastric mucosa and peptic ulcer (original project figure).



Figure 2. Aloe vera (Aloe barbadensis Miller) plant as presented in the original project.

2.4 Experimental groups and treatments

Five groups were described: Group I, normal control, receiving 0.5% carboxymethylcellulose (CMC; 10 mL/kg); Group II, standard control receiving omeprazole; Group III, untreated ulcer control; Group IV, Aloe vera extract 300 mg/kg; and Group V, Aloe vera extract 150 mg/kg. Oral treatment was reportedly administered once daily for 14 consecutive days. The source methods identify omeprazole as 10 mg/kg, while a complementary cytokine source labels its standard-control group as "Omeprazole 20 mg." This discrepancy must be checked; the datasets are not assumed to share identical dosing.

2.5 Ulcerogenic challenge and collection

The normal control reportedly received vehicle, while the other groups received an ulcerogenic agent described as "Alcohol" or ethanol on Day 14. The reported dose was 30 mg/kg, but the chemical identity, concentration, route and dose units are not sufficiently documented and must be confirmed. Animals were reportedly fasted for 24 hours, with water withdrawn two hours before challenge, and samples were collected two hours after challenge. Blood was collected by terminal cardiac puncture under deep anaesthesia, centrifuged at 3,000 × g for 10 minutes, and serum stored at −20 °C or below. Stomachs were excised, opened along the greater curvature, rinsed with saline and examined grossly; representative tissue was fixed in 10% neutral buffered formalin. The reported anaesthetic method, including chloroform mention in one source, requires verification against the approved protocol.

2.6 Gross lesion and ulcer assessment

The project describes gross examination of mucosal colour, hyperaemia, haemorrhagic spots and ulcer number, plus image-based lesion-area measurement using ImageJ. Ulcer index was described as the percentage of glandular mucosal area occupied by lesions, and percentage inhibition was planned as [(ulcer index of ulcer control − ulcer index of treated group)/ulcer index of ulcer control] × 100. No complete group-level ulcer-index or percentage-inhibition data were supplied; these outcomes are not presented.

2.7 Gastric-tissue antioxidant biomarkers (primary dataset)

MDA, SOD, CAT and GSH were reportedly measured in gastric-tissue homogenates using commercial kits (MDA Cat. No. YX-C-A401; SOD YX-C-A500; CAT YX-C-A501; GSH YX-C-A200) according to manufacturer instructions. Absorbance was read at kit-specified wavelengths. Results were reported as mean ± SEM. Kit details and the assay calculations should be verified from kit inserts and original records.

2.8 Serum cytokines (complementary dataset)

Serum TNF-α and IL-6 were reportedly measured using mouse-specific sandwich ELISA kits. Standards and samples were analysed in duplicate, absorbance read at 450 nm, and concentrations interpolated from standard curves and expressed as pg/mL. Kit manufacturers, catalogue numbers, detection limits and quality-control details were not available. These cytokine data came from a related project; the available records do not confirm that the same animals or identical protocols were used. Cytokine results are therefore presented separately and are not pooled with the antioxidant dataset.

2.9 Histopathology

Formalin-fixed gastric tissues were processed using routine paraffin histology, sectioned at approximately 4–5 μm and stained with haematoxylin and eosin. Sections were examined by light microscopy at ×100. Descriptive findings included epithelial necrosis, inflammatory-cell hyperplasia, glandular hyperplasia, mucosal distortion and normal architecture. Although a scoring system was mentioned in one source, individual component scores and group-level histological scores were not available; results are reported descriptively.

2.10 Statistical analysis

The primary dataset was reported as mean ± SEM and analysed by one-way ANOVA followed by Tukey's post-hoc test; Kruskal–Wallis testing was also reported for MDA. The complementary cytokine dataset was reported as mean ± SD and analysed using one-way ANOVA (TNF-α $F = 2.517$, $p = 0.108$; IL-6 $F = 3.490$, $p = 0.050$). Statistical analyses were not independently recalculated because raw individual-animal data and complete software outputs were unavailable. Significance was defined as $p < 0.05$. Original output should be checked, particularly the borderline IL-6 result and MDA omnibus finding.

3. Results

3.1 Gross gastric lesions (primary dataset)

No visible lesion was recorded in any of the three omeprazole-treated stomachs. All three untreated ulcer-control stomachs showed lesions. Two of three stomachs in the 300 mg/kg extract group showed haemorrhage/inflammation, while one appeared normal. All three stomachs in the 150 mg/kg group showed lesions. Unexpected swelling or haemorrhage was also recorded in two of three normal-control stomachs.

Table 1. Gross gastric mucosal lesions observed in mice following experimental gastric injury and treatment with Aloe vera extract or omeprazole.

Group	Mouse 1	Mouse 2	Mouse 3	Lesions (n/3)
Normal control	Swollen	Haemorrhage	No visible lesion	2/3
Omeprazole (reported 10 mg/kg)	No visible lesion	No visible lesion	No visible lesion	0/3
Untreated ulcer control	Inflammation and spot	Haemorrhage and inflammation	Bloated and haemorrhage	3/3
Aloe vera 300 mg/kg	Haemorrhage and inflammation	No visible lesion	Haemorrhage and inflammation	2/3
Aloe vera 150 mg/kg	Inflammation and haemorrhage	Inflammation	Haemorrhage	3/3

3.2 Gastric-tissue oxidative stress biomarkers (primary dataset)

SOD was lowest in the untreated ulcer control (0.72 ± 0.33 U/mL) and higher in the normal control and 150 mg/kg group (both 2.07 mean U/mL). The 300 mg/kg group recorded 1.77 ± 0.17 U/mL. CAT means were 0.10 ± 0.05 U/mL in the untreated ulcer control, 0.33 ± 0.15 at 300 mg/kg and 0.38 ± 0.31 at 150 mg/kg. GSH means were highly variable, with single high values driving the omeprazole and 150 mg/kg group means. MDA did not show a consistent protective pattern; the untreated ulcer-control mean was lower than the normal control, while the omeprazole mean was highest.

Table 2. Effects of Aloe vera extract and omeprazole on gastric tissue antioxidant biomarkers (superoxide dismutase, catalase, reduced glutathione, and malondialdehyde) in mice.

Group	SOD (U/mL)	CAT (U/mL)	GSH (µg/mL)	MDA (nmol/mL)
Normal control	2.07 ± 0.58	0.29 ± 0.13	0.85 ± 0.59	577.73 ± 88.90
Omeprazole 10	1.13 ± 0.29	0.07 ± 0.01	5.22 ± 4.75	992.20 ± 122.96
Untreated ulcer	0.72 ± 0.33	0.10 ± 0.05	0.63 ± 0.58	259.30 ± 29.54
Aloe vera 300	1.77 ± 0.17	0.33 ± 0.15	0.33 ± 0.29	250.80 ± 188.37
Aloe vera 150	2.07 ± 1.07	0.38 ± 0.31	3.74 ± 3.68	336.00 ± 282.75

3.3 Statistical comparisons of antioxidant biomarkers

Differences among groups were not statistically significant for SOD ($p = 0.425$), CAT ($p = 0.593$) or GSH ($p = 0.639$). MDA had an overall ANOVA $p = 0.048$, but Tukey's post-hoc analysis did not identify significant pairwise differences (lowest reported $p = 0.063$), and Kruskal–Wallis testing was not significant ($p = 0.106$). Thus, no pairwise differences were reported as statistically significant.

Table 3. Statistical comparison of gastric tissue antioxidant biomarkers among experimental groups using one-way analysis of variance, Kruskal–Wallis test, and Tukey's post-hoc analysis.

Parameter	F (4,10)	ANOVA p	Kruskal–Wallis p	Tukey post hoc
SOD	1.06	0.425	0.233	No significant pairs
CAT	0.73	0.593	0.427	No significant pairs
GSH	0.65	0.639	0.754	No significant pairs
MDA	3.53	0.048	0.106	No significant pairs (lowest p = 0.063)

3.4 Complementary serum inflammatory biomarkers

The related cytokine dataset showed the highest mean TNF-α and IL-6 in the untreated ulcer control. Both extract groups had lower mean cytokine concentrations than the untreated ulcer control. The overall TNF-α comparison was not significant ($p = 0.108$). The reported IL-6 omnibus p-value was 0.050; no significant pairwise differences were reported. These are descriptive trends from the complementary dataset, not pooled results.

Table 4. Serum concentrations of tumor necrosis factor-alpha (TNF-α) and interleukin-6 (IL-6) in mice across the experimental groups.

Group	TNF-α (pg/mL), mean ± SD	IL-6 (pg/mL), mean ± SD
Normal control	168.80 ± 79.07	36.28 ± 19.91
Omeprazole control*	174.59 ± 42.77	41.53 ± 21.12
Untreated ulcer control	330.43 ± 186.03	77.15 ± 18.58
Aloe vera 300 mg/kg	132.03 ± 38.15	37.58 ± 15.03
Aloe vera 150 mg/kg	112.03 ± 3.67	31.22 ± 7.39

*The complementary source labels the standard-control group "Omeprazole 20 mg"; units and equivalence to the primary dataset's omeprazole 10 mg/kg group require confirmation. Reported overall tests: TNF-α $F = 2.517$, $p = 0.108$; IL-6 $F = 3.490$, $p = 0.050$.

3.5 Gastric histology

Histological changes were mild to moderate, and none of the examined sections showed severe damage. Normal mucosal architecture was observed in two of three normal-control sections and two of three sections in the 300 mg/kg extract group; one normal section was recorded in each of the omeprazole, untreated ulcer-control and 150 mg/kg groups. Moderate findings included necrosis with inflammatory-cell hyperplasia in one omeprazole specimen and moderate inflammatory-cell hyperplasia in one 150 mg/kg specimen. Findings were descriptive and were not based on a validated group injury score.

Table 5. Qualitative histopathological observations of gastric tissues from mice in the normal control, omeprazole, untreated ulcer control, and Aloe vera-treated groups.

Group	Specimen observations	Overall description
Normal control	1: normal; 2: slight necrosis with inflammatory-cell hyperplasia; 3: normal	Two normal; one with mild changes
Omeprazole	4: moderate necrosis with inflammatory-cell hyperplasia; 5: slight necrosis; 6: normal	Mixed findings
Untreated ulcer control	7: slight necrosis; 8: glandular hyperplasia; 9: normal	Mixed findings
Aloe vera 300 mg/kg	10: normal; 11: slight mucosal distortion with slight inflammatory-cell hyperplasia; 12: normal	Two normal; one with mild changes
Aloe vera 150 mg/kg	13: normal; 14: moderate inflammatory-cell hyperplasia; 15: slight necrosis	Mixed findings

Panels are grouped by treatment and presented in the original sample order. Images are reproduced from the first manuscript and have not been interpreted beyond the descriptive findings reported in the source.

Normal control (A–C)

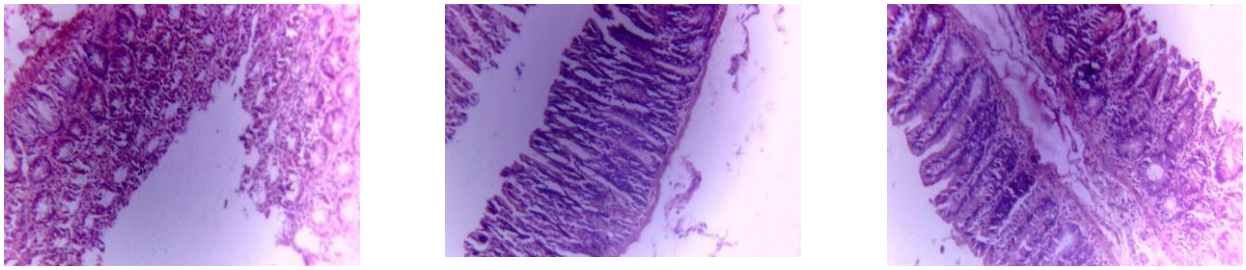

Omeprazole (D–F)

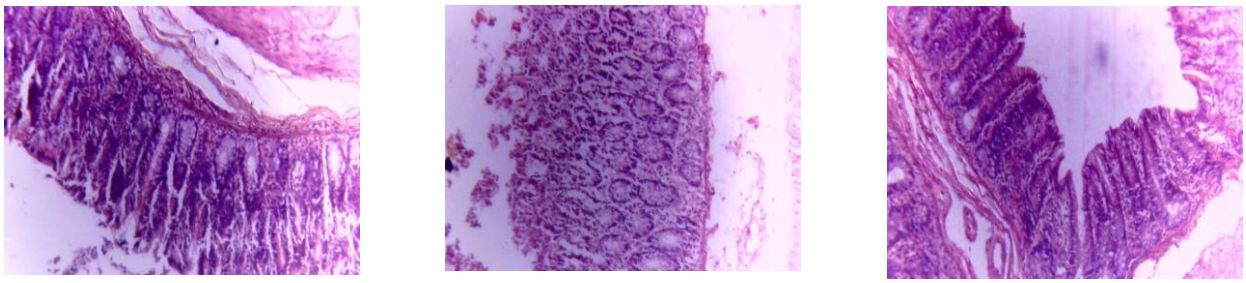

Untreated ulcer control (G–I)

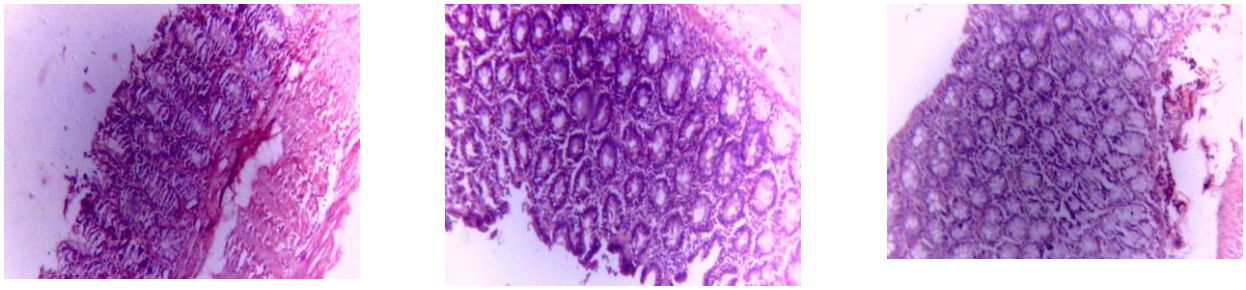

Aloe vera 300 mg/kg (J–L)

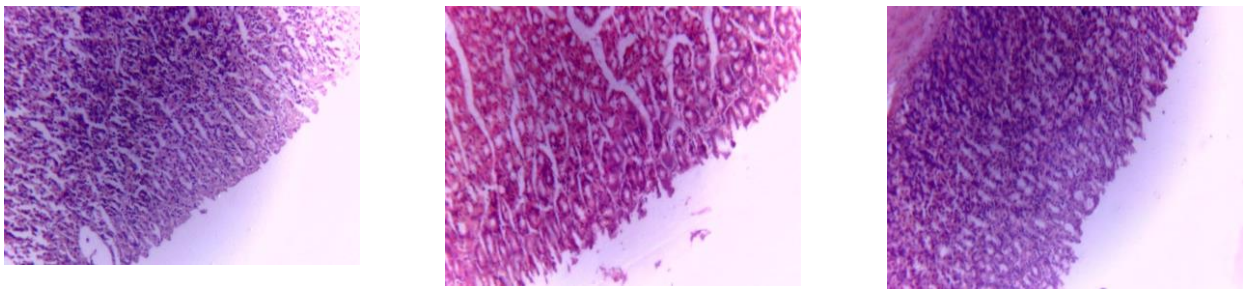

Aloe vera 150 mg/kg (M–O)

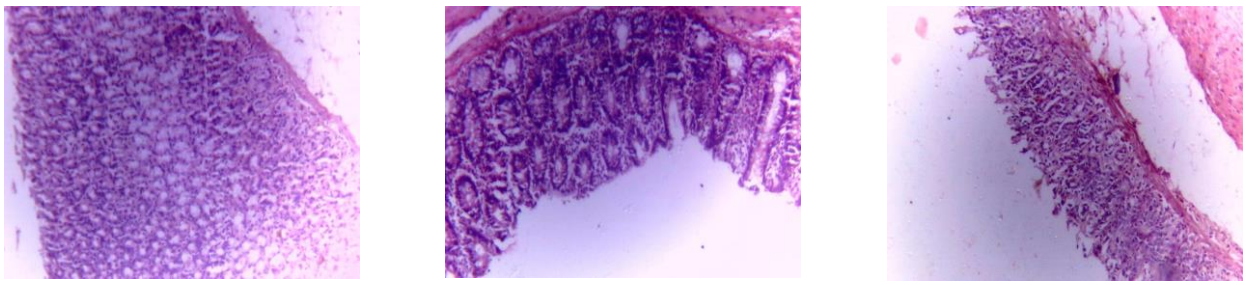

Plate I. Original gastric histology photomicrographs (H&E, ×100)

4. Discussion

The gross findings distinguished the untreated ulcer control, in which all three stomachs showed lesions, from the omeprazole group, in which no visible lesion was recorded. Two of three stomachs in the 300 mg/kg Aloe vera group appeared lesioned, while one appeared normal; all three stomachs at 150 mg/kg showed lesions. This pattern does not establish gastroprotection, but it provides descriptive observations for follow-up. Previous studies have reported fewer ethanol-related gastric lesions following Aloe vera polymer fractions or gel preparations (Park et al., 2011, 2017), and other experimental work has reported gastroprotective changes after Aloe-containing interventions (Eamlamnam et al., 2006; Werawatganon et al., 2014; Hussein et al., 2021; Mohamed et al., 2024). The present lesion observations are less conclusive because sample size is small and quantitative ulcer-index data are missing.

SOD and CAT means in both extract groups were higher than those in the untreated ulcer control, a pattern biologically compatible with antioxidant defense. Ethanol-induced gastric injury has been linked to redox imbalance and mitochondrial dysfunction, while Aloe vera preparations have been investigated for their effects on oxidative-stress markers in experimental gastric injury (Pan et al., 2008; Hussein et al., 2021; Mohamed et al., 2024; Raish et al., 2021). However, the differences in the present dataset were not statistically significant, and variability—particularly in the 150 mg/kg group—was large. These findings should not be described as demonstrated antioxidant efficacy or a dose-response relationship.

GSH and MDA results were inconsistent with a simple protective pattern. The omeprazole and 150 mg/kg GSH means were influenced by single high observations, while MDA was highest in the omeprazole group and lower in the untreated ulcer control than in the normal control. Such patterns may reflect biological variability, small group size, assay variability or baseline differences; these possibilities cannot be resolved without raw data, assay validation and repeat experiments. The marginal MDA ANOVA result is not supported by significant pairwise comparisons or the non-parametric test and should not be overinterpreted.

The complementary cytokine dataset showed lower mean TNF-α and IL-6 in both extract groups than in the untreated ulcer control. This is consistent with the role of inflammatory signalling in ethanol-related mucosal injury and with experimental reports that Aloe-containing interventions may influence cytokine responses and related inflammatory pathways (Eamlamnam et al., 2006; Hussein et al., 2021; Mohamed et al., 2024; Raish et al., 2021). Nevertheless, TNF-α was not statistically significant, and IL-6 was borderline at $p = 0.050$ with no reported significant pairwise comparisons. Since the source records do not confirm the same animals or identical treatment protocols, cytokines cannot be merged with antioxidant data for a unified statistical analysis.

Histology showed mild-to-moderate changes across groups. Two of three specimens in the 300 mg/kg group were described as normal, but normal sections were also present in control groups, and some abnormalities occurred in the normal control. This variability reinforces the need for blinded quantitative histological scoring, clearly defined criteria, representative images, and adequate sample size. The observations are qualitative and cannot establish tissue protection.

The study has substantial limitations: only three animals per group are represented in the results; the planned 25 animals and analyzed 15 animals are not reconciled; ulcer-index and percentage-inhibition data are missing; the challenge agent, dose, units and route are uncertain; omeprazole dose labels differ; histological scores were not supplied; ELISA kit information and original statistical output are incomplete; and the relationship between the cytokine and antioxidant datasets is unconfirmed.

These limitations should be addressed before submission. The combined data support hypothesis-generating observations only and do not establish gastroprotective, antioxidant or anti-inflammatory efficacy.

5. Conclusion

In the primary dataset, all untreated ulcer-control stomachs showed gross lesions, while none of the omeprazole-treated stomachs did. Lesions were recorded in two of three mice at 300 mg/kg and all three mice at 150 mg/kg Aloe vera extract. SOD and CAT means were higher in extract-treated groups than in the untreated ulcer control, but differences were not significant. GSH and MDA showed inconsistent patterns. Complementary cytokine results showed lower mean TNF-α and IL-6 in extract groups than in the untreated ulcer control, but pairwise statistical significance was not established. Histology was mild-to-moderate and descriptive. These findings are exploratory; the available data do not demonstrate efficacy. Larger, adequately powered experiments with verified protocols, complete ulcer-index outcomes, validated histological scoring and confirmed shared sampling are required.

6. References

Awaad, A. S., El-Meligy, R. M., & Soliman, G. A. (2013). Natural products in treatment of ulcerative colitis and peptic ulcer. Journal of Saudi Chemical Society, 17(1), 101–124.

Bancroft, J. D., & Gamble, M. (2019). Theory and practice of histological techniques (8th ed.). Elsevier.

Bi, W. P., Man, H. B., & Man, M. Q. (2014). Efficacy and safety of herbal medicines in treating gastric ulcer: A review. World Journal of Gastroenterology, 20(45), 17020–17028.

Eamlamnam, K., Patumraj, S., Visedopas, N., & Thong-Ngam, D. (2006). Effects of Aloe vera and sucralfate on gastric microcirculatory changes, cytokine levels and gastric ulcer healing in rats. World Journal of Gastroenterology, 12(13), 2034–2039.

Hamman, J. H. (2008). Composition and applications of Aloe vera leaf gel. Molecules, 13(8), 1599–1616.

Lanas, A., & Chan, F. K. L. (2017). Peptic ulcer disease. The Lancet, 390(10094), 613–624.

Medzhitov, R. (2008). Origin and physiological roles of inflammation. Nature, 454(7203), 428–435.

Park, C. H., Nam, D. Y., Son, H. U., Lee, S. R., Lee, H. J., Heo, J. C., Cha, T. Y., Baek, J. H., & Lee, S. H. (2011). Polymer fraction of Aloe vera exhibits a protective activity on ethanol-induced gastric lesions. International Journal of Molecular Medicine, 27(4), 511–518.

Park, C. H., Son, H. U., Yoo, C. Y., & Lee, S. H. (2017). Low molecular-weight gel fraction of Aloe vera exhibits gastroprotection by inducing matrix metalloproteinase-9 inhibitory activity in alcohol-induced acute gastric lesion tissues. Pharmaceutical Biology, 55(1), 2110–2115.

Percie du Sert, N., et al. (2020). The ARRIVE guidelines 2.0: Updated guidelines for reporting animal research. PLOS Biology, 18(7), e3000410.

Sung, J. J. Y., Kuipers, E. J., & El-Serag, H. B. (2009). Systematic review: The global incidence and prevalence of peptic ulcer disease. Alimentary Pharmacology & Therapeutics, 29(9), 938–946.

Sánchez, M., González-Burgos, E., Iglesias, I., & Gómez-Serranillos, M. P. (2020). Pharmacological update: Properties of Aloe vera and its major active constituents. Molecules, 25(6), 1324.

Tanaka, T., Narazaki, M., & Kishimoto, T. (2014). IL-6 in inflammation, immunity, and disease. Cold Spring Harbor Perspectives in Biology, 6(10), a016295.

Wallace, J. L. (2008). Prostaglandins, NSAIDs, and gastric mucosal protection: Why doesn't the stomach digest itself? Physiological Reviews, 88(4), 1547–1565.

Werawatganon, D., Rakananurak, N., Sallapant, S., Prueksapanich, P., Somanawat, K., Klaikeaw, N., & Rerknimitr, R. (2014). Aloe vera attenuated gastric injury on indomethacin-induced gastropathy in rats. World Journal of Gastroenterology, 20(48), 18330–18337.

Hussein, J., El-Bana, M. A., El-Naggar, M. E., Abdel-Latif, Y., El-Sayed, S. M., & Medhat, D. (2021). Prophylactic effect of probiotics fortified with Aloe vera pulp nanoemulsion against ethanol-induced gastric ulcer. Toxicology Mechanisms and Methods, 31(9), 699–710. https://doi.org/10.1080/15376516.2021.1958112

Mohamed, A. O., Abd-Elghaffar, S. K., Mousa, R. A., & Kamel, A. (2024). Aloe vera gel confers therapeutic effect by reducing pyroptosis in ethanol-induced gastric ulcer rat model: Role of NLRP3/GSDMD signaling pathway. Molecular Biology Reports, 51, Article 401. https://doi.org/10.1007/s11033-024-09329-4

Pan, J.-S., He, S.-Z., Xu, H.-Z., Zhan, X.-J., Yang, X.-N., Xiao, H.-M., Shi, H.-X., & Ren, J.-L. (2008). Oxidative stress disturbs energy metabolism of mitochondria in ethanol-induced gastric mucosa injury. World Journal of Gastroenterology, 14(38), 5857–5867. https://doi.org/10.3748/wjg.14.5857

Raish, M., Shahid, M., Bin Jardan, Y. A., Ansari, M. A., & Alkharfy, K. (2021). Gastroprotective effect of sinapic acid on ethanol-induced gastric ulcers in rats: Involvement of Nrf2/HO-1 and NF-κB signaling and antiapoptotic role. Frontiers in Pharmacology, 12, 622815. https://doi.org/10.3389/fphar.2021.622815